

Supernumerary Orbital Muscle in Congenital Eyelid Retraction

Esther L. Wylen, M.D.,*† Mark S. Brown, M.D.,* Leonard S. Rich, M.D.,*
and Richard J. Hesse, M.D.*†

**Department of Ophthalmology, University of South Alabama Medical Center, Mobile, Alabama and*
†*Department of Ophthalmology, Alton Ochsner Medical Foundation Hospital, New Orleans, Louisiana, U.S.A.*

Purpose: Although several reports of supernumerary orbital muscles related to the levator palpebrae superioris have been published, no case has been associated with congenital eyelid retraction. This report describes an apparent causal relationship between an accessory levator muscle slip and congenital eyelid retraction.

Methods: Case report and literature review.

Results: Release of the anomalous muscle's attachment from the superior tarsal border alone resulted in resolution of the eyelid retraction.

Conclusions: Eyelid muscle anomalies may be a cause of congenital eyelid retraction. Ophthalmologists who treat eyelid disorders should be aware of this possibility when evaluating and operating on patients with congenital eyelid retraction.

Supernumerary orbital muscles have occasionally been described.¹⁻⁷ Rush and Schaeffer⁵ observed that many shared a common origin with the levator palpebrae superioris. The most consistently reported anomalous orbital muscle is the so-called muscle tensor trochleae of Budge, more recently known as the levator trochlear muscle³ or tendon.¹ This muscle consistently originates with the medial border of the levator and inserts into the trochlea.^{1,3-5} We report an anomalous muscle found in the upper eyelid of a child during surgery for congenital eyelid retraction. The muscle inserted on the nasal superior tarsal border and extended toward the orbital apex. Unlike the levator-trochlear muscle, it did not extend nasally to the trochlear area. This represents another finding of an upper eyelid muscle anomaly and also the first reported case of a muscle abnormality associated with congenital eyelid retraction.

CASE REPORT

A 4-year-old boy was referred to the oculoplastics service with left upper eyelid retraction that the parents reported (and verified with photographs) had been present and stable since birth (Fig. 1). The child was the product of an uncomplicated term pregnancy and non-forceps-assisted spontaneous vaginal delivery, with a negative medical history and normal developmental milestones. There was no history of thyroid disease, facial trauma, seventh nerve palsy, previous eyelid surgery, hepatic disease, or use of sympathomimetic medications. General physical examination was unremarkable, with no dysmorphic features other than the unilateral eyelid abnormality. There was no facial weakness or asymmetry aside from the eyelid retraction. Ophthalmologic examination revealed a superior marginal reflex distance of 11 mm on the left with a palpebral fissure height of 14 mm. The contralateral marginal reflex distance was 3 mm with a palpebral fissure height of 7 mm, thus excluding contralateral ptosis. Levator function was normal bilaterally. There was 5 mm of lagophthalmos on the left side and none on the right. Bell's phenomenon was intact bilaterally. Muscle balance, cycloplegic refraction, and head position all were normal. There was neither eyelid

Accepted September 22, 2000.

Address correspondence and reprint requests to Dr. Mark S. Brown, Director of Eye Plastics, Department of Ophthalmology, University of South Alabama, P.O. Box 8448, Mobile, AL 36689-0448, U.S.A.

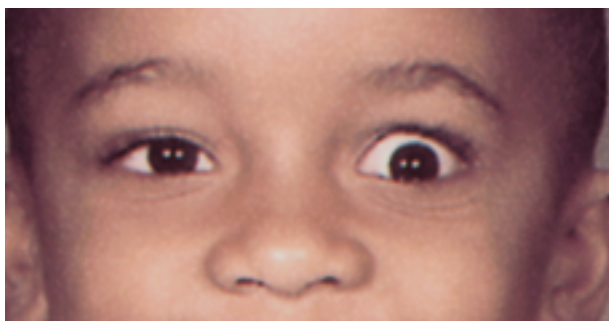

FIG. 1. Four-year-old boy with congenital left upper eyelid retraction.

lag nor any evidence of a jaw-winking phenomenon or other anomalous innervation. Magnetic resonance imaging of the brain and orbits showed no abnormalities, and thyroid function tests were within normal limits. The presumptive diagnosis of congenital eyelid retraction was made.

The child was brought to surgery for a planned levator recession of the left upper eyelid. The levator aponeurosis was disinserted from its insertion along the superior tarsal border across the entire length of the eyelid using cautery. An anomalous muscle was identified inserting along the nasal portion of the superior tarsal border alongside the levator, piercing the levator aponeurosis and heading toward the orbital apex (Fig. 2). This muscle was released at the superior tarsal border, resulting in resolution of both the eyelid retraction and lagophthalmos intraoperatively. Because the exact nature of this muscle could not be discerned, it was sutured to the orbital rim with 6-0 Mersilene (Ethicon, Somerville, NJ) polyester sutures so that

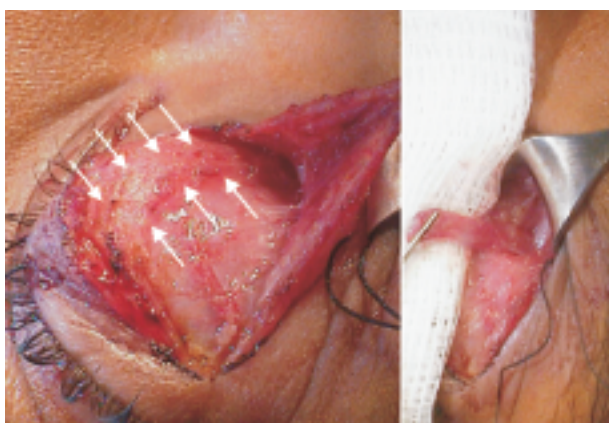


FIG. 2. Intraoperative photograph of anomalous muscle inserting along the nasal portion of the superior tarsal border.

it could be further manipulated if deemed necessary at a later time. The levator aponeurosis was then reapproximated at the site of its original attachment, with no recession performed to prevent overcorrection. Postoperative eyelid position was improved but still very slightly elevated compared with the normal fellow eyelid (Fig. 3). Lagophthalmos was completely resolved. Muscle balance was normal postoperatively.

DISCUSSION

Anomalous muscle slips related to the levator palpebrae superioris have been found by some authors to be present in 10% to 14% of specimens.^{2,4} The one most commonly cited is a supernumerary muscle originally described as the tensor trochleae muscle of Budge^{4,6} and more recently renamed the levator-trochlear muscle by Sacks.³ This muscle originates from the medial border of the levator and extends variably to the trochlea and nearby structures.³ Bartley¹ found a similar structure, a tendon extending from the trochlear area to the anterior inferior levator aponeurosis in a child with congenital blepharoptosis (Fig. 4). Other structures that run longitudinally with the levator, which are more similar to the one we report here, have been described in the early anatomic literature.⁷

Congenital retraction of the upper or lower eyelid is a poorly defined entity about which little is known.⁷ The disorder has only been reported as unilateral. The diagnosis is made when eyelid retraction is present from birth in the absence of trauma, thyroid disease, proptosis, or abnormalities of cranial nerves III or VII. Inferior rectus restriction with an overacting superior rectus-levator

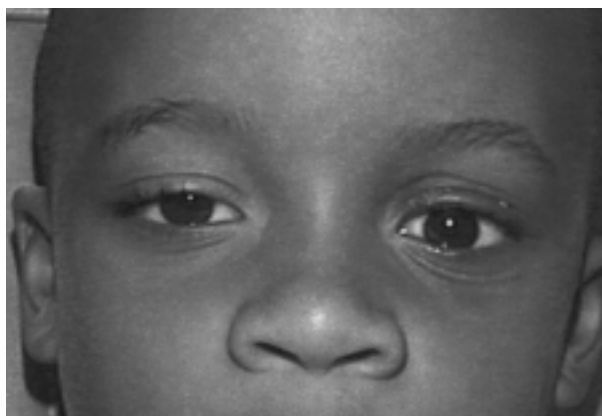


FIG. 3. Postoperative appearance with improved eyelid position.

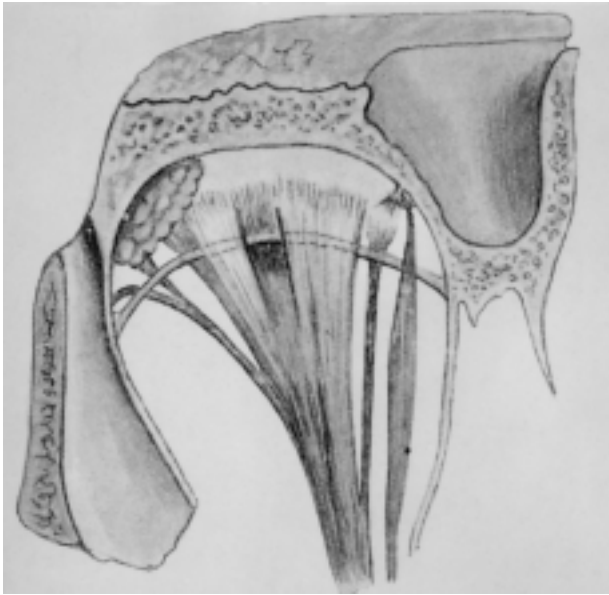


FIG. 4. Drawing of anomalous levator muscle slip, from Whitnall (Reprinted with permission from Oxford University Press, reference 6, p. 145).

complex must be excluded, as must Marcus-Gunn jaw-winking phenomenon. Associations with strabismus, anisometropic amblyopia, and Down syndrome have been reported,^{8,9} but their significance is unknown. No underlying cause has been identified, although one case was cited to have thickened lateral and medial levator horns (possibly as a result of congenital orbital fibrosis or intrauterine infection) as a cause.¹⁰ No supernumerary orbital muscles have been reported to cause eyelid retraction until the present case.

We describe an anomalous muscle slip related to the levator muscle, extending from the medial border of the levator's insertion on the tarsus posteriorly towards the orbital apex. This muscle occurred in the eyelid of a 4-year-old child with congenital upper eyelid retraction, and disinsertion of the muscle from the tarsus produced a normal eyelid position. Similar supernumerary structures have been described, but none in association with eyelid retraction. We conclude that anatomical variants of the levator muscle can in some cases be responsible for eyelid position abnormalities. The possibility of structural variants such as the one we encountered should be considered by ophthalmologists when evaluating and treating idiopathic eyelid malpositions.

REFERENCES

1. Bartley GB. An anomalous trochlea-levator "tendon" observed during congenital blepharoptosis surgery. *Ophthalm Plast Reconstr Surg* 1989;5:288-90.
2. Von Ludinghausen M. Bilateral supernumerary rectus muscles of the orbit. *Clin Anat* 1998;11:271-7.
3. Sacks JG. The levator-trochlear muscle. A supernumerary orbital structure. *Arch Ophthalmol* 1985;103:540-1.
4. Whitnall SE. Some abnormal muscles of the orbit. *Anat Rec* 1921;21:143-52.
5. Rush CC, Schaeffer JP. Supernumerary orbital muscles. *Arch Ophthalmol* 1917;46:524-7.
6. Whitnall SE. *The anatomy of the human orbit and accessory organs of vision*. London: Oxford Medical Publications, 1921:144-5, 284.
7. Howe L. *The muscles of the eye*. Vol. I. New York: GP Putnam's Sons, 1907:51-4.
8. Collin JRO, Castronuovo S. Congenital eyelid retraction. *Br J Ophthalmol* 1990;74:542-4.
9. Rovit AJ, Deupree DM, Zang Y-F, Biglan AW. Treatment of congenital unilateral eyelid retraction with a marginal myotomy procedure. *Ophthalmic Surg* 1988;19:872-5.
10. Leone CR, Lewis R. Congenital upper eyelid retraction. *J Pediatr Ophthalmol* 1976;13:350-2.