

Concomitant Ocular Injuries With Orbital Fractures

Mark S. Brown, MD*

Willy Ky, MD†

Richard D. Lisman, MD‡

Abstract:

Background and Objectives. The orbital floor may fracture alone, and the fracture is then defined as "pure"; when there is a rim involvement, the fracture may be defined as "impure." Controversy exists as to the pathophysiology of orbital floor fractures and the incidence of orbital rim involvement. The purpose of this retrospective review was to determine the incidence of purity in orbital floor blowout fractures and the rate of ocular injuries in pure and impure floor fractures.

Methods and Materials. The charts of 250 patients with orbital fractures, treated at a primary trauma center between 1992 and 1996, were reviewed. All fractures had been examined by the Ophthalmology Service and confirmed by high-resolution computerized tomography scans. The average age of the patients was 45 years; more than 90% were male. Motor vehicle accidents were the most commonly documented mechanism of injury, followed by interpersonal violence and falls. Almost 50% could not be categorized for mechanism of injury.

Results and/or Conclusions. The incidence of ocular injuries in pure fractures ($n=54$; 5.6%) was higher than in impure fractures ($n=26$; 2.0%) ($p=0.05$). Serious visual injuries following orbital fractures occurred in 17.1% of the patients; they were more common in patients with pure fractures.

*Department of Ophthalmology, New York University School of Medicine, New York, New York. Department of Ophthalmology, University of South Alabama College of Medicine, Mobile, Alabama.

†Department of Ophthalmology, New York University School of Medicine, New York, New York. Department of Ophthalmology, Washington University/Barnes, St. Louis, Missouri.

‡Department of Ophthalmology, New York University School of Medicine, New York, New York.

Address correspondence and reprint requests to: Mark S. Brown, MD, P.O. Box 8448, Mobile, AL 36689, Tel: 334-460-6388, Fax: 334-460-6349, E-mail: Fractures@EyePlastics.com

Orbital fractures are among the most common mid-facial fractures encountered in trauma centers.^{1,2} In a review of 400 patients with facial fractures resulting from motor vehicle accidents (MVAs), 9% of the fractures involved the orbital floor.³ In another review of 567 facial fracture patients, 16% were orbital floor fractures and 3.4% were recorded as "severe eye injuries," including those resulting in loss of vision.⁴ This type of injury was first described in 1889 by Lang.⁵ Since then, there has been a significant expansion of knowledge in diagnosis and treatment of orbital fractures.

However, a controversy has always existed as to the pathophysiology of orbital floor fractures and the incidence of rim involvement.⁶ The orbital floor may fracture alone or in combination with the orbital rim. Three theories have been proposed to explain the mechanism of orbital floor fractures. Smith and Regan⁷ and Pfeiffer⁸ believe that a sudden increase in intraorbital pressure, when applied in an anterior/posterior direction and resulting in the pressure dissipation 90° to the

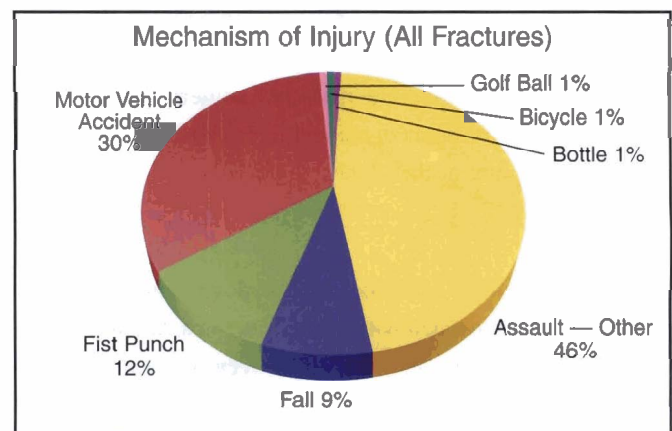


Figure 1. Motor vehicle accidents (MVAs) were the most commonly documented mechanism of injury, accounting for 30% of the fractures, followed by blows of a fist (12%) and falls (9%). Almost 50% of the injuries could not be categorized.

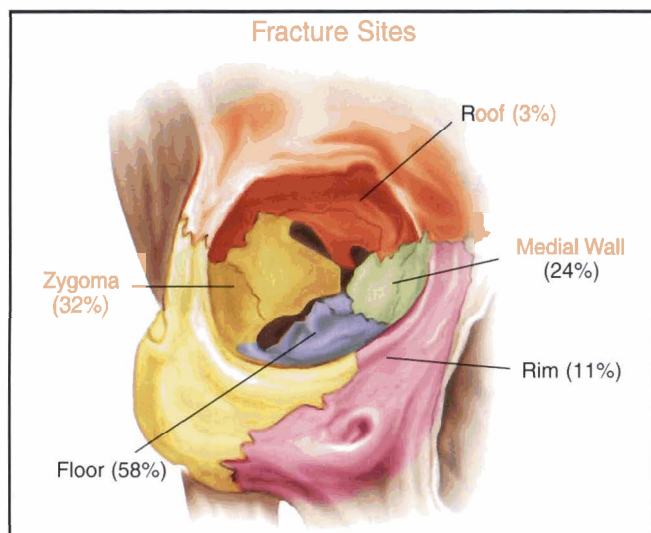


Figure 2. There were 302 orbital fractures among the 250 patients. (The percentages indicated exceed 100%, since many patients sustained multiple fractures.) Fracture of the orbital floor was most common (138 patients, 58%), followed by zygoma (72 patients, 32%) medial wall (52 patients, 24%), inferior orbital rim (28 patients, 11%), and roof (7 patients, 3%).

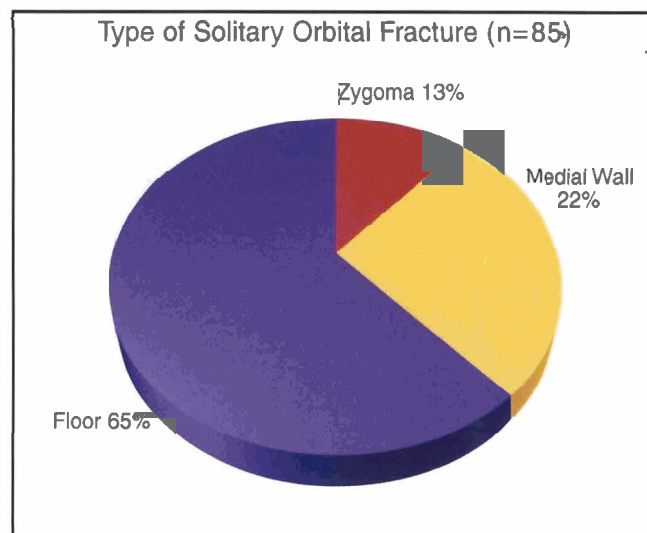


Figure 3. An isolated fracture was present in 85 patients. A pure orbital blowout fracture of the floor (no orbital rim involvement) was the most common (54 patients, 65%), followed by medial wall fracture (18 patients, 22%).

line of force, may cause a “blowout” of the thin orbital floor; this explanation is known as the “retropulsion” theory. In contrast, Fujino^{9,10} and Manson¹¹ believe that the force may be transmitted to the orbital floor through the rigid orbital rim, without causing a fracture of the orbital rim; this theory is known as the “buckling force” theory. Recently, Erling et al¹² revisited an original theory of the mechanism of orbital blowout fractures, initially proposed in 1943 by Pfeiffer.⁸ This theory proposed that a direct “globe-to-wall” contact was responsible for some orbital blowout fractures. They contend that this is a third and often unrecognized mechanism responsible for orbital blowout fractures. If the orbital rim is fractured, the term “impure” floor fracture is used.^{6,7,12} The mechanism of an impure fracture is not one of debate. To our knowledge, there has never been a study investigating the relationship between the purity of orbital fractures and concomitant ocular injuries. The ocular complications of orbital fractures are numerous, ranging in severity from periorbital edema and ecchymosis to optic nerve trauma and rupture of the globe.

METHODS

Various publications have attempted to document the types of ocular injuries associated with orbital fractures, but no study to date has elucidated the relationship between ocular injuries and the purity of orbital floor fractures. To investigate the relationship, a retrospective review was performed of 250 consecutive charts of patients with orbital fractures, evaluated by the Ophthalmology Service at Bellevue Hospital in New York City between 1992 and 1996. The protocol of this hospital requires

that all patients with orbital fractures receive an ophthalmic examination. The clinical evaluation of the fractures of all 250 patients, including dilated examinations of all, was confirmed by orbital high-resolution computerized tomography (CT) scans.

Logs from the CT scans were reviewed to identify any additional patients with orbital fractures; no additional patients were identified. This information was used to determine:

- The incidence of purity in orbital floor fractures.
- The rate of concurrent ocular injuries of pure and impure fractures. The definition of ocular injury was based on those used in previous reports in the literature.^{2,13-21} It included ruptured globe, vitreous hemorrhage, angle recession, corneal abrasion, iritis, hyphema, afferent pupillary defect (APD), retinal detachment, dislocated lens, traumatic cataract, choroidal rupture, commotio retinae, macular cyst, and retinal edema.
- The incidence of medial wall involvement with orbital floor fractures.
- Whether there was a difference in the rate of intraocular injuries between pure and impure fractures. A Chi-Square test was used.

RESULTS

Demographics and Mechanism of Injury

The average age of the patients was 45 years, ranging from 15 to 75 years; more than 90% of the patients were male. There is a suggestion of a bimodal distribution of age for orbital fractures, with peaks at ages 21 to 30 years and at 41 to 50 years.

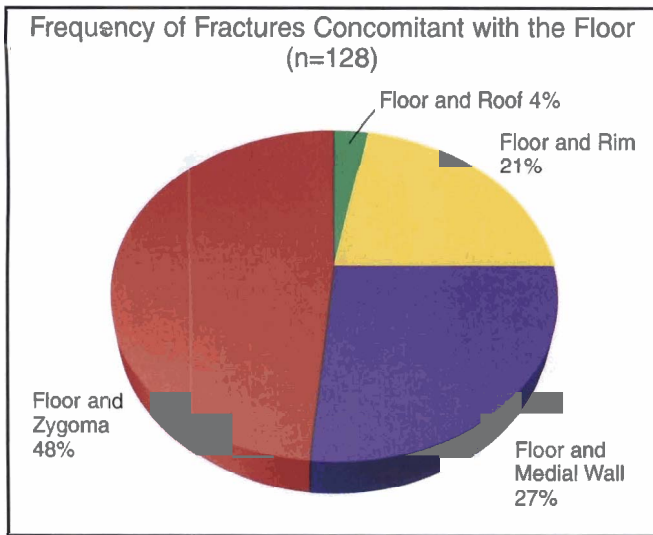


Figure 4. The chart shows the frequency of fractures concomitant with the orbital floor. The most common fracture is a zygoma (57 patients, 48%) followed by medial wall fracture (30 patients, 27%), and orbital rim (26 patients, 21%).

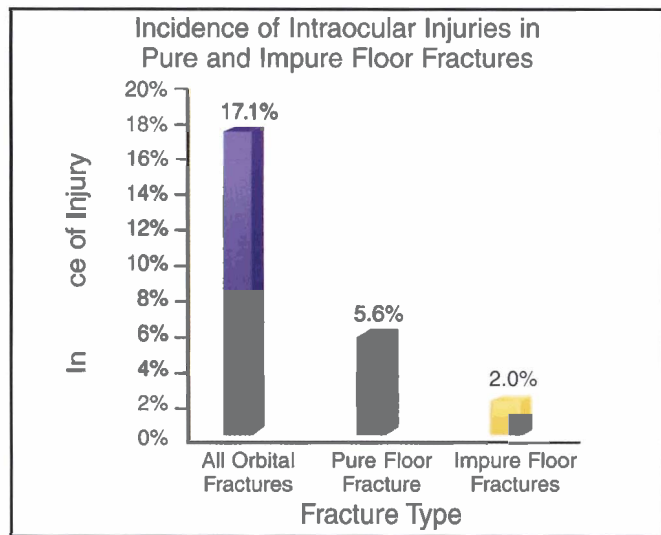


Figure 5. The incidence of intraocular injuries with orbital fractures is approximately 17%. The rate of injury was compared between pure orbital fractures (floor only) and impure (floor and rim). Intraocular injuries occurred in 5.6% of patients with a pure orbital floor fracture and in 2.0% with an impure fracture.

Motor vehicle accidents were the most commonly documented mechanism of injury, accounting for 30% of the fractures, followed by interpersonal violence (blow by a fist, 12%) and falls (9%). Due to the lack of chart documentation, almost 50% of the injuries could not be categorized for mechanism of injury (Figure 1).

Types of Fracture

There were 302 fractures among the 250 patients. The most common fracture was the orbital floor (138 patients, 58%) (Figure 2). Of the 250 patients, 85 had an isolated fracture. The most common of the 85 fractures was a pure orbital fracture (54 patients, 65%), followed by medial wall fracture (18 patients, 22%) (Figure 3). Of the 250 patients, 128 had a fracture concomitant with an orbital floor fracture. The most common fracture to occur in combination with the orbital floor was zygoma (57 patients, 48%), followed by medial wall (30 patients, 27%), and orbital rim (26 patients, 21%) (Figure 4).

Incidence of Ocular Injury

Applying the above definition of ocular injury, we found the incidence of ocular injury (all orbital fractures) to be 17.1% (Figure 5). The incidence of injury in pure orbital fractures (floor only) and impure orbital fractures (floor and rim) was also compared. Of the patients who sustained a pure orbital floor fracture, intraocular injuries occurred in 5.6%; only 2.0% sustained an impure fracture (Figures 5 and 6). The incidence of eye injuries in patients with pure fractures (n=54) versus impure fractures (n=26) (Chi-Square=36.2, $p=0.05$) is presented (Figure 6).

DISCUSSION

When orbital bones are fractured, intraocular injuries occur in various patterns. Numerous studies emphasize the importance of an ophthalmic examination in patients with orbital fractures; however, only a limited number of studies have focused on the incidence of intraocular injuries in patients with orbital fractures. In these studies, there is no consensus as to the incidence of injury. It is possible that the specialty of the physician conducting the research may account for the inconsistencies.⁴ The previous studies reporting incidences of intraocular injury concomitant with orbital floor fractures are listed in the Table. There is a wide spectrum of incidence from the 1% of McCoy¹⁹ to the nearly 70% of Holt.² Another variable to consider when comparing trauma studies is the location of the treating facility. This study was performed in a large major metropolitan area where there are fewer high-speed motor vehicle accidents than in the western segment of the United States. In addition, the difference in the incidence of violent crime varies with the geographic region.

The results of the intraocular injury incidence were 17%, as previously defined. Although we believe our data to be complete, it is possible that some patients may have been excluded inadvertently. Such exclusion may have occurred if the patient did not receive an orbital CT scan, an ophthalmic examination, or if the fracture was diagnosed by plain films. If exclusions have occurred, the incidence of ocular injury may be slightly different.

Three theories of mechanism have been formulated and are known as the "retropulsion," "buckling," and "globe-to-wall" theories of mechanism.

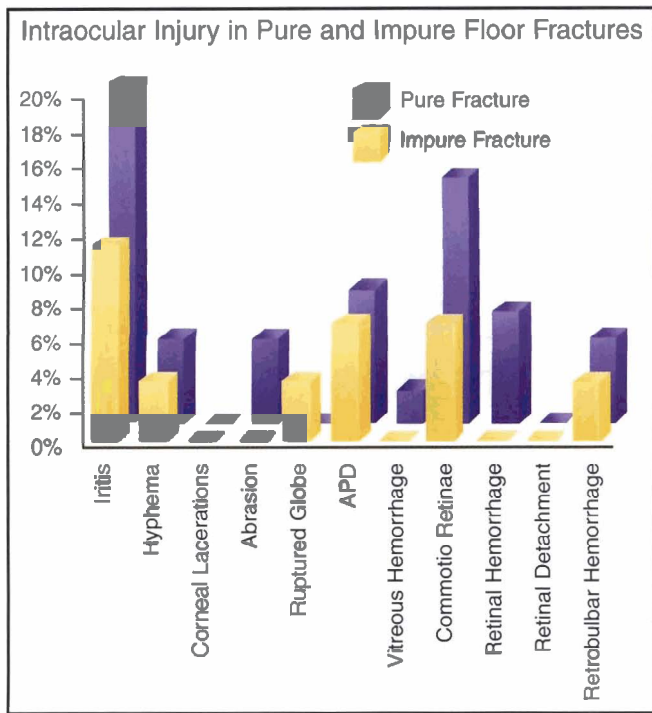


Figure 6. The rate of eye injuries in patients with pure fractures (54) versus impure fractures (26) were as follows: Iritis: 20.4% versus 11.5%. HypHEMA: 5.6% versus 3.8%. Corneal laceration: 0.0% versus 0.0%. Corneal abrasion: 5.6% versus 0.0%. Ruptured globe: 0.0% versus 3.9%. APD (Afferent pupillary defect): 9.4% versus 7.7%. Vitreous hemorrhage: 1.9% versus 0.0%. Comotio retinae: 14.8% versus 7.7%. Retinal hemorrhage: 7.4% versus 0.0%. Retinal detachment: 0.0% versus 0.0%. Retrolbulbar hemorrhage: 5.6% versus 3.95%.

Lang was the first to publish a case of an orbital floor fracture in a 13-year-old boy with enophthalmos and diplopia.⁵ He identified this fracture as a case of “traumatic enophthalmos with retention of perfect visual acuity.” Pfeiffer was the first to hypothesize a theory as to the mechanism for orbital

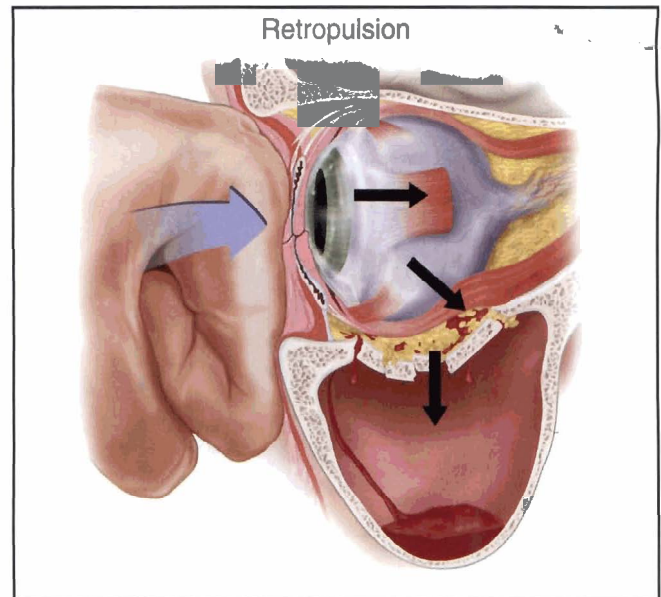


Figure 7. The “retropulsion” theory of Pfeiffer, advanced by Smith and Regan, refers to a fracture of the orbital floor, caused by force applied to the aperture of the orbit, *retropulsing* the globe posteriorly and inferiorly, creating a fracture.

floor fractures.⁸ He reviewed 120 cases of fractures of the facial bones with orbital involvement and suggested from the results of the review that pure orbital blowout fractures were caused by the transmission of the force of injury toward the orbital floor directly from the retropulsed globe. The cadaver experiments conducted by Smith and Regan⁷ found that the force created by striking a hurling ball over the globe in a cadaver was capable of reproducing an orbital floor fracture (without rim involvement). When the same force was used to strike the ball on a cadaver with the globe enucleated, no fracture was produced (Figure 7).

Table

Concomitant Ocular Injuries With Orbital Floor Fractures						
Author	Year Published	No. of Patients	% Evaluated by Ophthalmologist	% of Patients with Ocular Injuries *	Comments	
McCoy ²⁰	1962	855	Unknown	1%	A,C	
Milauskas ¹⁶	1966	84	100%	14%	A,B	
Miller ¹⁷	1967	30	100%	17%	A,B	
Fradkin ¹⁵	1971	53	85%	40%	A,B	
Gwyn ⁴	1971	1517	Unknown	3.5%	C	
Jabaley ¹⁵	1975	57	11%	18.4%	C,R	
		49	100%	29%	C,P	
Holt ¹⁵	1983	727	51%	67%	A,B	
Brown et al	Current Study	250	100%	17.1%	B	

A = Rim involvement not specifically detailed
 B = Ophthalmologist conducting the study
 C = Plastic surgeon conducting the study
 R = Retrospective portion of the study
 P = Prospective portion of the study
 *Variable of 2°, depending how “injury” is defined.

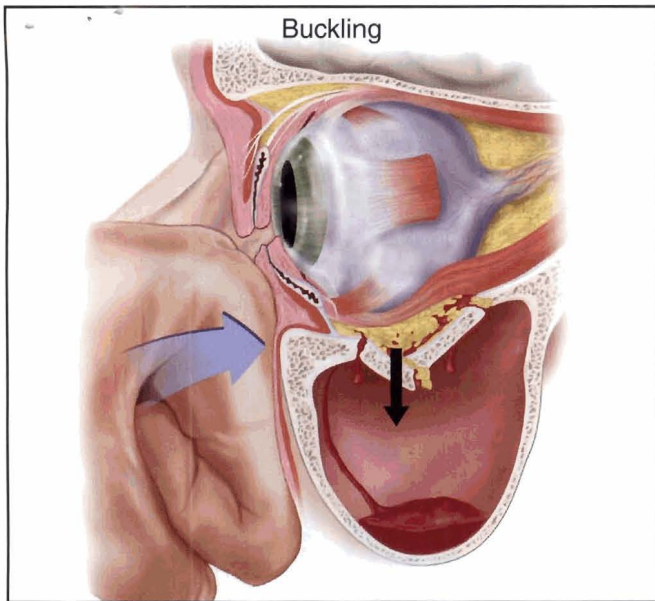


Figure 8. The “buckling” theory maintains that an anterior force is transmitted *through the rim* back into the orbital floor, causing the floor to *buckle*.

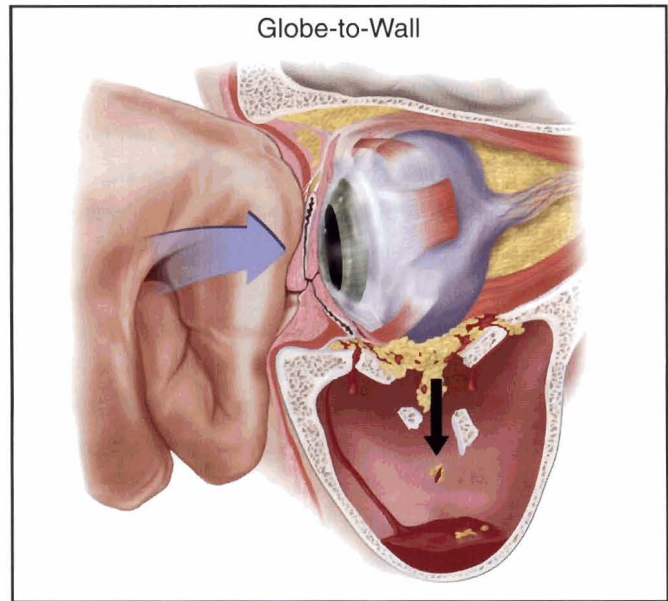


Figure 9. The “globe-to-wall” theory states that if the globe is displaced to within 2.5 cm of the orbital apex, *the globe itself fractures the orbital wall*.

This theory was challenged by the experiments of Fujino.⁹ In 1974, Fujino was able to reproduce an orbital fracture without rim involvement by striking the inferior orbital margin of a dried-out human skull, thereby demonstrating that “hydraulic pressure from the orbital content against the orbital floor was not essential for the development of an orbital “blowout fracture.” Subsequently, Fujino and Sato¹⁰ found that the impact on the eyeball and infraorbital margin resulted in fractures that were similar to those resulting from impact on the infraorbital margin alone. Exertion of a greater force was required to produce orbital floor fracture when striking the eyeball alone (Figure 8). Both these experiments supported the theory first hypothesized by Le Fort,²¹ who also believed that orbital floor fractures were produced by the force of the injury, transmitted through the orbital rim directly to the floor.

The third theory is an extension of Pfeiffer’s theory and was formulated in 1999 by Erling et al.¹² It states that if the globe is displaced to within 2.5 cm from the orbital apex, the globe itself fractures the orbital wall (Figure 9).

By definition, pure blowout fractures do not involve simultaneous fractures of the orbital rim.⁴ According to Putterman et al, orbital floor fractures involving the orbital rim are entirely different entities, differing in etiology, results, and treatment.²² Lauer et al proposed a classification system based upon the location of the fracture, its relationship to the infraorbital nerve, and its association to other facial fractures, particularly the zygomatico-orbital and Le Fort fractures.²³ It was found in this study that even though pure and impure fractures may be associated with fractures on both sides of the infraorbital nerve,

pure fractures tend to be medial to the infraorbital nerve while impure fractures tend to be lateral.

The rates of injury were also compared between pure orbital floor fractures (floor only) and impure (floor and rim). Of patients who sustained a pure orbital floor fracture, intraocular injuries occurred in 5.6%, compared with only 2.0% of the patients who sustained an impure fracture. Intraocular injuries are more common in patients with pure orbital fractures than in patients with rim involvement (impure) ($p=0.05$). However, the rate of a ruptured globe is higher with impure orbital fractures than with pure fractures.

We find that the incidence of ocular injury is significantly higher in the pure fracture group, thereby suggesting that a different mechanism may be involved. It is more reasonable to hypothesize that the acute rise in orbital pressure will lead not only to a fracture of the orbital floor but also to a greater incidence of intraocular injury as the globe retropulses. It could be argued, however, that in the case of the impure fracture, the rate of injury is lower because the force is blunted by the rim. Nevertheless, we believe that these data suggest (but not completely clarify) whether the retropulsion theory is a more likely explanation for orbital fractures. Either theory — retropulsion, buckling, or globe-to-wall — could explain variations of ocular findings in pure and impure fractures.

CONCLUSION

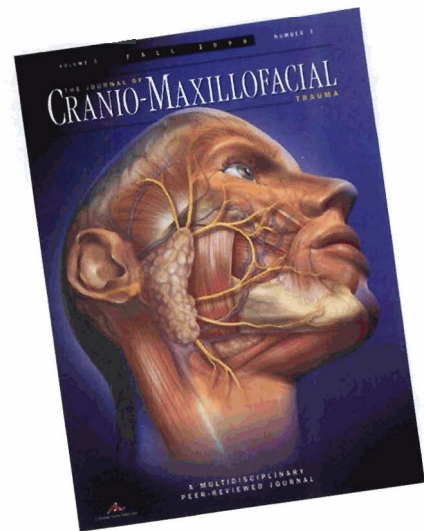
Serious ocular injuries may result from a wide range of midfacial fractures. Although they are more common in tripod fractures, the incidence in orbital floor and medial wall

fractures is nevertheless significant.²¹ The ocular sequelae of midfacial fractures range from vision-nonthreatening injuries (including iritis, ecchymosis, and edema of the soft tissues, nasolacrimal disturbances, commotio retinae, and ptosis) to vision-threatening injuries (including ruptured globe, vitreous hemorrhage, diplopia, retrobulbar hemorrhage, and the optic nerve and retinal detachments). Long-term vision-threatening injuries following orbital fractures are uncommon; however, the incidence of intraocular injuries, based on our definition, is approximately 17%. This incidence is consistent with previous studies in which 100% of the patients were examined by an ophthalmologist. Intraocular injuries are more common in patients who sustain pure orbital fractures than in patients with rim involvement (impure). Pure orbital fractures are twice as common as impure orbital fractures. The medial wall is fractured in approximately 30% of floor fractures.

REFERENCES

1. Greene D, Raven R, Carvalho G, Maas CS. Epidemiology of facial injury in blunt assault. Determinants of incidence and outcome in 802 patients. *Arch Otolaryngol Head Neck Surg* 1997;123(9):923-928.
2. Holt JE, Holt GR, Blodgett JM. Ocular injuries sustained during blunt facial trauma. *Ophthalmol* 1983;90(1):14-18.
3. Schultz RC. Facial injuries from automobile accidents: A study of 400 consecutive cases. *Plast Reconstr Surg* 1967;40(5):415-425.
4. Gwyn PP, Carraway JH, Horton CE, et al. Facial fractures — Associated injuries and complications. *Plast Reconstr Surg* 1971;47(3):225-230.
5. Lang W. Traumatic enophthalmos with retention of perfect acuity of vision. *Trans Ophthalmol Soc United Kingdom, England*: 1889;9:41-48.
6. Lisman RD, Barna N, Smith B. Internal orbital fractures: Controversies in the surgical decision. In: *Problems in Plast Reconstr Surg*, Manson PN, ed. 1991;1(2): 365-395.
7. Smith B, Regan WF Jr. Blow-out fracture of the orbit: Mechanism and correction of internal orbital fracture. *Am J Ophthalmol* 1957;44:733-739.
8. Pfeiffer RL. Traumatic enophthalmos. *Arch Ophthalmol* 1943;30:718-726.
9. Fujino T. Experimental "blowout" fracture of the orbit. *Plast Reconstr Surg* 1974; 54(1):81-82.
10. Fujino T, Sato TB. Mechanisms, tolerance limit curve and theoretical analysis in blow-out fractures of two- and three-dimensional orbital wall models. *Proceedings of the Third International Symposium on Orbital Disorders*. Amsterdam, Holland: Excerpta Medica 1977:240-247.
11. Manson PN, Grivas A, Rosenbaum A, et al. Studies on enophthalmos: II. The measurement of orbital injuries and their treatment by quantitative computed tomography. *Plast Reconstr Surg* 1986;77(2):203-214.
12. Erling BF, Iliff N, Robertson B, Manson PN. Footprints of the globe: A practical look at the mechanism of orbital blowout fractures, with a revisit to the work of Raymond Pfeiffer. *Plast Reconstr Surg* 1999;103(4):1313-1316.
13. Dutton J, Slamovits T. Management of blow-out fracture of the orbital floor. *Surv Ophthalmol* 1990;35:279-298.
14. Dodick JM, Galin MA, Kwitko ML. Concomitant blowout fracture of the orbit and rupture of the globe. *Arch Ophthalmol* 1970;84(6):707-709.
15. Fradkin A. Orbital floor fractures and ocular complications. *Am J Ophthalmol*. 1977;72(4):699-700.
16. Milauskas AT, Fueger GF. Serious ocular complications associated with blowout fractures of the orbit. *Am J Ophthalmol* 1966;62(4):670-672.
17. Miller GR, Tenzel RR. Ocular complications of midfacial fractures. *Plast Reconstr Surg* 1967;39(1):37-42.
18. Jabaley ME, Lerman M, Sanders HJ. Ocular injuries in orbital fractures. A review of 119 cases. *Plast Reconstr Surg* 1975;56(4):410-418.
19. McCoy FJ, Chandler RA, Magnan CG, et al. An analysis of facial fractures and their complications. *Plast Reconstr Surg* 1962;29:381-391.
20. Grossman MD, Roberts DM, Barr CC. Ophthalmic aspects of orbital injury. A comprehensive diagnostic management approach. *Clin Plast Surg* 1992;19(1): 71-85.
21. Le Fort R. *Proceedings from the XIII Congress of International Medicine* 1901;23:275. (Cited In: Duke-Elder WS. *Textbook of Ophthalmology*. St. Louis, MO: Mosby, 1954, Volume 6).
22. Putterman AM, Stevens T, Urist MJ. Nonsurgical management of blow-out fractures of the orbital floor. *Am J Ophthalmol* 1975;14:467-470.
23. Lauer SA, Snyder B, Rodriguez E, Adamo A. Classification of orbital floor. *J Cranio-Maxillofac Trauma* 1996;2:6-11.

**Continue to Receive
the Only Journal Dedicated
to Trauma Treatment
SUBSCRIBE TODAY**



- Peer Reviewed
- Detailed Medical Illustrations
- Full-Color Case Photography
- Multidisciplinary
- Clinically Relevant
- Technique Presentations

**Annual Rates for a
Quarterly Subscription**

(Please check one)

U.S.A.

Individual \$95.00

Student \$78.00

Institution \$108.00

CALL TODAY

1-800-899-5350

**or subscribe online at
www.montagemedia.com**



**MONTAGE MEDIA
CORPORATION**

1000 WYCKOFF AVENUE • MAHWAH, NJ 07430
800-899-5350 • 201-891-3200 • FAX 201-891-2626